

## A Foreign Body Reaction to a Contraceptive Implant

AkhilB Shah<sup>1</sup>, Vien Lam<sup>1</sup>, Mostafa A Borahay<sup>1,2</sup>, Pooja R Patel<sup>1,\*</sup>

<sup>1</sup>Department of Obstetrics and Gynecology, The University of Texas Medical Branch in Galveston, TX, USA

<sup>2</sup>Department of Cell Biology, The University of Texas Medical Branch in Galveston, TX, USA

\*Corresponding author: Pooja R. Patel, Department of Obstetrics and Gynecology, The University of Texas Medical Branch, 301 University Boulevard, Galveston, TX 77555-0587; Tel: (409)772-6019; E-mail: popatel@utmb.edu

Received Date: February 06, 2014 Accepted Date: February 22, 2014 Published Date: February 24, 2014

Citation: Pooja R Patel, et al. (2014) A Foreign Body Reaction to a Contraceptive Implant. J Womens Health Gynecol 1: 1-3

### Abstract

**Background:** With the increased use of the single-rod subdermal implant, clinicians will be gradually exposed to previously unknown adverse effects from the device. It is important for us to share these experiences with our colleagues.

**Case:** In this case report, we present the outcome of a 20 year old female who experienced a foreign body reaction to the subdermal implant.

**Conclusion:** Subdermal contraceptive implants may lead to foreign body reactions which may result in spontaneous expulsion of the implant.

### Introduction

As the most effective form of contraception available, the subdermal contraceptive implant has gained increased popularity. The device has evolved over the past decades from a system of six Silastic (Dow Corning, Midland, MI) silicone rubber capsules containing 36 mg of levonorgestrel powder, to a single rod containing 68 mg of etonogestrel surrounded by a non-biodegradable membrane of ethylene vinylacetate copolymer [1,2]. With the increased use of this device, clinicians will be exposed to more adverse effects. In this case report, we present the outcome of a 20 year old female who experienced a superinfected foreign body reaction to the subdermal implant. To the best of our knowledge, this is the first report of such a reaction to the subdermal contraceptive implant.

### Case report

A 20 year old patient with no significant past medical history, presented to her clinic 2 months postpartum for the insertion of a subdermal contraceptive implant, which was placed without difficulty. She called the clinic 5 days later complaining of redness, swelling, itching and pain at the implant site. The patient was told to apply cold compresses, take Tylenol and

call back if the symptoms worsened. The patient called back a month later stating that the swelling had increased and now was only isolated to the skin above the edges of the implant (Figure 1). On a nurse-visit exam, her vital signs were within normal limits and the site was described as "red and swollen, concerning for an allergic reaction". The patient was then immediately referred to a nurse practitioner for implant removal. The nurse practitioner attempted removal however aborted it as it was difficult and there was a concern for infection, given the purulent drainage which could be expressed from each of the two lesions. The patient was given a 1-week course of Bactrim and returned again to see the same nurse practitioner for removal. At this point a third pustular lesion was noted at the incision site where the removal was previously attempted. The patient was told to continue Bactrim and was given a follow-up appointment with a physician to attempt removal. The patient presented to the gynecologist's clinic and the lesions appeared infected with purulent drainage (Figure 1). There was a concern that an attempt at removal may seed the blood with bacteria, therefore cultures of the lesions were obtained, antibiotics were changed to Keflex and patient was told to follow-up in 1 week. When the patient presented to her follow-up clinic visit, she informed the physician that earlier that day she had noticed the implant protruding out of one of the pustular lesions, so the patient had pulled the implant out herself. Of note, the previous culture grew back methicillin-resistant staphylococcus, susceptible to both Bactrim and Clindamycin; therefore, the

antibiotics were switched to Clindamycin. One month later, the patient noted resolution of the lesions.

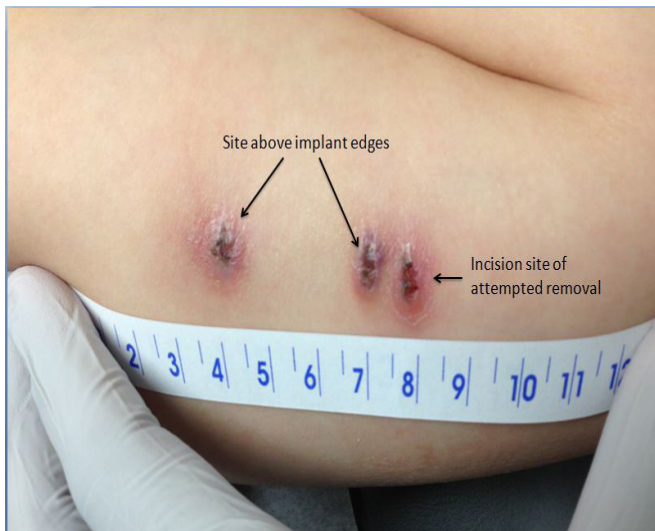


Figure. 1

## Discussion

To the best of our knowledge, this is the first report of what appears to be a foreign body reaction, specifically a granuloma, to a subdermal contraceptive implant which resulted in spontaneous expulsion. When biomaterials are implanted into humans, a variety of host reactions can ensue, including acute and chronic inflammation, fibrous capsule development, or a foreign body reaction [3-5]. The formation of fibrous capsules around subdermal contraceptive implant is a frequently reported phenomenon [6]. However, the process of a foreign body reaction to such an implant has not been published in the literature. In this process, injury to vascularized connective tissue initiates an intense inflammatory response and thrombus formation which subsequently activates the complement system, resulting in the deposition of a provisional matrix on a biomaterial surface. The cytokines and growth factors on this matrix result in modulation of macrophage activity and mast cell degranulation with subsequent histamine release, marking the acute inflammatory response to the implanted biomaterial [7-9]. Following this acute inflammatory response, chronic inflammation occurs with the predominance of mononuclear cells. This process usually lasts no more than a couple of weeks; if the response persists beyond this time period, then an infection is usually present [10]. What was interesting about this case was the fact that the granuloma formation was isolated to the tips of the implant and not around the long axis of the implant. This may be due to the fact that with arm movement, the implant edges protrude and irritate the surrounding tissue more than the long axis of the implant. Another peculiar characteristic of this patient's presentation was the fact that a similar lesion formed at the site of incision for removal, a site which had no contact with the implant (Figure 1). The only plausible explanation we could conceive is that the hemostat came into contact with the tip of the implant and contaminated the incision site as the hemostat was pulled out.

Another important feature of foreign body reac-

tions is the fact that macrophages and foreign body giant cells that adhere to the implant can result in degradation of biomaterials with subsequent device failure [11,12]. In the case of a foreign body reaction to a subdermal implant, it is unknown whether this may result in failure of the contraceptive. Therefore, it would have been prudent to prescribe a second form of contraception while the foreign body reaction is being managed.

We were unable to find any report of such a reaction to either the Norplant® capsules or the current Implanon®/Nexplanon® subdermal implant. We were, however, able to find a report from 1997 on an anaphylactoid reaction after insertion of the Norplant® capsules that resolved spontaneously and did not require removal of the capsules. Additionally, it was unclear whether this reaction was to the capsules or the local anesthesia. We were also able to find a retrospective review on outcomes of 190 women who had Implanon® insertions that briefly mentioned two infections, however details regarding the infection were not given, and the fact that one of the infections was 6 months post-insertion makes a foreign body reaction unlikely [13]. The only other report we were able to find pertaining to the extrusion of subdermal implants was in the scenario of subdermal testosterone implants [14]. Like the subdermal contraceptive implants, the testosterone implants are inserted via an applicator; however, unlike the rod shape of the contraceptive implants, the testosterone implants are small pellets. The pathophysiology of these extrusions is unclear, however the extrusions usually occur 2 months after placement [15]. In their study of 262 testosterone implantations, Kelleher et al found that 29 resulted in extrusions, however only 6 of these were associated with signs of an infection [14].

In conclusion, foreign body reactions may occur in response to contraceptive implants, which may result in spontaneous expulsion. Nevertheless, the spontaneous expulsion of the implant suggests that such a reaction may not need intervention from the medical provider. In fact, further intervention may have caused bacteremia, as the infection would have had to be traversed in order to remove the implant. A larger analysis is warranted to determine the best management strategy for these cases.

## References

- 1) Nelson AL, Sinow RM (1998) Real-time ultrasonographically guided removal of nonpalpable and intramuscular Norplant capsules. *Am J Obstet Gynecol* 178: 1185-1193.
- 2) Persaud T, Walling M, Geoghegan T, Buckley O, Stunell H, et al. (2008) Ultrasound-guided removal of Implanon devices. *Eur Radiol* 18: 2582-2585.
- 3) Anderson JM (2000) Multinucleated giant cells. *Curr Opin Hematol* 17: 40-47.
- 4) Gretzer C, Emanuelsson L, Liljensten E, Thomsen P (2006) The inflammatory cell influx and cytokines changes during transition from acute inflammation to fibrous repair around implanted materials. *J Biomater Sci Polym Ed* 17: 669-687.

- 5) Luttikhuisen DT, Harmsen MC, Van Luyn MJ (2006) Cellular and molecular dynamics in the foreign body reaction. *Tissue Eng* 12: 1955-1970.
- 6) James P, Trenery J (2006) Ultrasound localisation and removal of non-palpable Implanon implants. *Aust N Z J Obstet Gynaecol* 46: 225-228.
- 7) Wu Y, Simonovsky FI, Ratner BD, Horbett TA (2005) The role of adsorbed fibrinogen in platelet adhesion to polyurethane surfaces: a comparison of surface hydrophobicity, protein adsorption, monoclonal antibody binding, and platelet adhesion. *J Biomed Mater Res A*, 74: 722-738.
- 8) Zdolsek J, Eaton JW, Tang L (2007) Histamine release and fibrinogen adsorption mediate acute inflammatory responses to biomaterial implants in humans. *J Transl Med* 5: 31.
- 9) Tang L, Jennings TA, Eaton JW (1998) Mast cells mediate acute inflammatory responses to implanted biomaterials. *Proc Natl Acad Sci U S A* 95: 8841-8846.
- 10) Anderson JM, Rodriguez A, Chang DT (2008) Foreign body reaction to biomaterials. *Semin Immunol* 20: 86-100.
- 11) Zhao QH, McNally AK, Rubin KR, Renier M, Wu Y, et al. (1993) Human plasma alpha 2-macroglobulin promotes in vitro oxidative stress cracking of Pellethane 2363-80A: in vivo and in vitro correlations. *J Biomed Mater Res* 27: 379-388.
- 12) Kao WJ, Zhao QH, Hiltner A, Anderson JM (1994) Theoretical analysis of in vivo macrophage adhesion and foreign body giant cell formation on polydimethylsiloxane, low density polyethylene, and polyetherurethanes. *J Biomed Mater Res* 28:73-79.
- 13) Smith A, Reuter S (2002) An assessment of the use of Implanon in three community services. *J Fam Plann Reprod Health Care* 28: 193-196.
- 14) Kelleher S, Turner L, Howe C, Conway AJ, Handelsman DJ (1999) Extrusion of testosterone pellets: a randomized controlled clinical study. *Clin Endocrinol (Oxf)* 51: 469-471.
- 15) Handelsman DJ, Mackey MA, Chris Howe, Leo Turner, Conway AJ (1997) An analysis of testosterone implants for androgen replacement therapy. *Clin Endocrinol (Oxf)* 47: 311-316.

**Submit your manuscript to a JScholar journal and benefit from:**

- ¶ Convenient online submission
- ¶ Rigorous peer review
- ¶ Immediate publication on acceptance
- ¶ Open access: articles freely available online
- ¶ High visibility within the field
- ¶ Better discount for your subsequent articles

Submit your manuscript at  
<http://www.jscholaronline.org/submit-manuscript.php>