

Multiple Myeloma Following Bladder Cancer Successfully Treated With Bortezomib: A Case Report and Review of Literature

Yihao Wang¹, Fengping Peng¹, Rong Fu¹, Wenjing Song² and Zonghong Shao^{1,*}

¹Department of Hematology, General Hospital, TianJin Medical University, No.154, HePing District, TianJin 300052, China

²Department of Pathology, General Hospital, TianJin Medical University, No.154, HePing District, TianJin 300052, China

***Corresponding author:** Zong-Hong Shao, Department of Hematology, General Hospital, TianJin Medical University, No.154, HePing District, TianJin 300052, China. Tel: +86 22 60362085; Fax: +86 22 60362086; Email: shao-zonghong@sina.com

Received Date: December 16, 2013; **Accepted Date:** February 20, 2014; **Published Date:** February 22, 2014

Citation: Yihao Wang, et al. (2013) Multiple myeloma following bladder cancer successfully treated with Bortezomib: A case report and review of literature. J Cancer Res Therap Oncol 1: 1-5

Abstract

The incidence of Multiple Myeloma (MM) following other malignancies is extremely rare. To our knowledge, only 23 cases of this condition have been reported. This study is the first to report on an incidence of MM following bladder cancer after treatment with intravesical Pharmorubicin RD instillation in a 71-year-old male patient. The etiopathology of this specific condition is discussed with an emphasis on two pathogenic features, namely, anthracyclines and gene mutation, which may have been involved in MM development. Regimen consisting of bortezomib may be used as a clinical basis for future treatment of MM following other malignancies.

Keywords: Multiple myeloma; Bladder cancer; Gene mutation; Bortezomib

Introduction

Multiple myeloma (MM) following other malignancies is a rare type of malignant plasma cell disorder. To the best of our knowledge, only 23 cases of MM following other malignancies and its coexisting symptoms have been documented in PubMed MEDLINE [1-23] (Table. 1). MM can occur after the appearance of solitary tumors, such as those in lung cancer and gastric cancer, or hematological malignancies, such as MyeloProliferative Neoplasm (MPN) and lymphoma. We report the first case of a patient with MM following bladder cancer. The satisfactory clinical recovery of this patient after treatment with bortezomib is also discussed.

Case report

A 71-year-old male patient was admitted to the Second Affiliated Hospital of TianJin Medical University in January 2010 after being diagnosed with approximately one-month

totally painless gross hematuria. The patient did not have a history of dysuria, urinary urgency, or urethral discharge that could indicate an infectious or inflammatory process. No fever was evident, but the patient occasionally complained of blood clot discharges and flank pain. B-scan ultrasound revealed multiple hypoechoic masses or nodules in the anterior bladder wall and bladder neck. Complete blood count, renal function, and globulin levels were normal. No other evidence of metastatic disease was found elsewhere in the body. Transurethral Resection of Bladder Tumor (TURBT) was performed. The pathological diagnosis was low-grade papillary transitional epithelium carcinoma (Figure. 1). After four cycles of intravesical Pharmorubicin RD instillation (50 mg/m², day 1; one week/cycle) after surgery, the patient exhibited satisfactory clinical recovery. However, a follow-up B-scan ultrasound evaluation five months after chemotherapy revealed hyperechoic uplifted shapes on both sides of the bladder neck, which suggested relapse of bladder cancer. No symptoms and abnormalities were found upon laboratory examination. Cystoscopic examination and TURBT were again performed. Pathological analysis revealed intrinsic-membrane fibrous tissue hyperplasia, as well as chronic inflammation in the tissue overlying the transitional epithelium. No

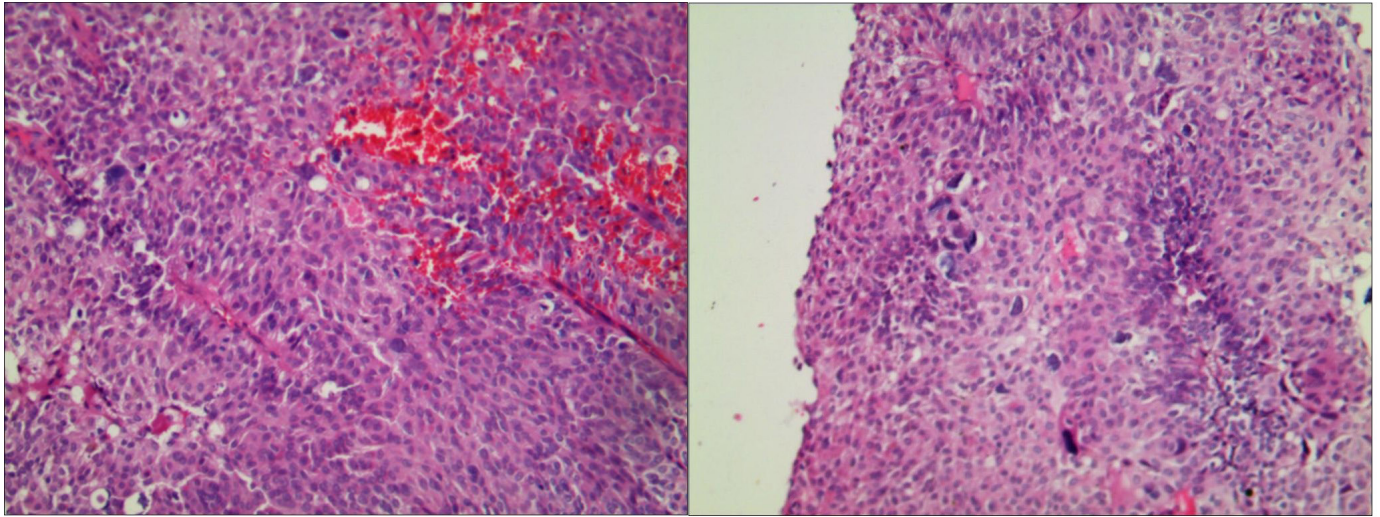


Figure. 1 Bladder wall masses biopsy showing low-grade papillary transitional epithelium carcinoma, H-E $\times 100$

evidence of recurrence was observed, and no further therapy (including chemotherapy) was provided for four months after the last surgery.

In July 2011, the patient was again referred to the hospital with major complaints of intermittent fever and pain in both lower limbs. The blood count [hemoglobin (Hb) 81 g/L; mean corpuscular volume, 81.7 fl; mean corpuscular hemoglobin concentration, 328 g/L; white blood cell and platelet counts, normal] indicated normocytic, normochromic anemia. The bone marrow contained an excess of plasma cells (40.0%) (Figure. 2). Immunohistochemical analysis of the bone marrow showed that the tumor cells were positive for monoclonal κ light chains, CD38, and CD138, but negative for CD79a, CD5, and CD10. Flow cytometric results are as follows: R5 2.0%: CD38 (47.8%), CD138 (31.1%), CD56 (40.2%), and CD20 (-).

Immunoelectrophoresis and immunofixation showed a spike in the γ globulin region corresponding to a monoclonal protein (M protein) in the serum and in the urine. The patient had hyperglobulinemia (IgA 3550.0 mg/dL, κ light chain 2810.0 mg/dL), with a noticeably high κ/λ ratio of 30:1. The creatinine level was 108 $\mu\text{mol/L}$. Plasma albumin (ALB) and lactate

dehydrogenase levels were normal (37 g/L and 128 U/L, respectively). The $\beta_2\text{M}$ level was increased (6.56 mg/L). Serum C-reactive protein concentration was 2.98 mg/dl.

A skeletal survey revealed multiple lytic bone lesions in ribs 4, 7, and 8. The adjusted serum calcium concentration was 2.69 mmol/L. Both cytogenetic and FISH analysis indicated a normal karyotype (46, XX [9]). Both *ras* and *p53* gene mutations were detected in the bone marrow mononuclear cells by reverse transcription-polymerase chain reaction.

A diagnosis of multiple myeloma (IgA κ) was given (Durie-Salmon Clinical staging IIIA, ISS stage III). The patient was then treated with one cycle of "VDZ" (1.3 mg/m² bortezomib, d 1, 4, 8, and 11; 40/m² dexamethasone, d1, 8, 15, and 22; and 4 mg/m² zoledronic acid, d1) for chemotherapy. CBC was normal. Bone marrow aspiration and biopsy showed 3% plasma cell. Serum protein electrophoresis and immunofixation indicated the presence of IgA κ monoclonal protein. Bence-Jones proteinuria was again detected (806 mg/dl IgA, 1080 mg/dl κ light chain, and 7.1:1 κ/λ ratio), and good partial remission was achieved based on the evaluation. The patient further received two regular cycles of "VDZ" chemotherapy

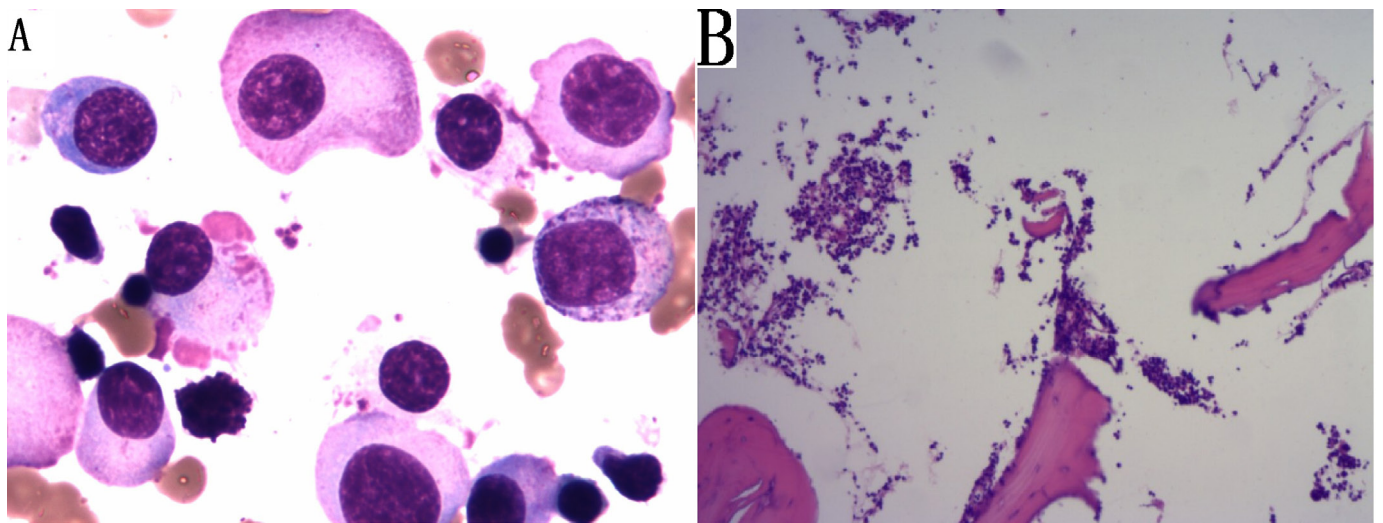


Figure. 2 A) Bone marrow aspirate smear demonstrating large numbers of plasma cells with eccentric round nucleus and condensed chromatin, some of plasmablast with basophilic cytoplasm. Wright-Giemsa. $\times 1000$. B) Bone marrow trephine biopsy showing extensive infiltration of neoplastic plasma cells, H-E $\times 100$

Authors, year	Age/sex	Malignancies before MM	Treatment before MM	Malignancies-MM interval	SPE/IE	Treatment after MM	Outcome	Abnormal chromosome/gene
Drasin H et al., 1979	50 F	Lung Lymphocytic lymphoma	Radiation therapy	9 years	IgG	MOP	Died after 28 months	NS
Claudia W et al., 1999	57 M	T-cell lymphoma	PUVA + INF α 2b	2 years	IgG λ	alkeran+ decortin	Died after 28 months	NS
Muzaffer K et al., 2013	68 M	Colon adenocarcinoma gastrointestinal stromal tumor lung cancer	folinic acid 5-fluorouracil irinotecan bevacizumab	15 months	IgG κ	Chemotherapy and biphosphonate	Died after 18 months	K-RAS mutation t(4;14),17p13,
Vassilia G. et al., 2005	68 M	CML	INF α Imatinib	18 months	IgG λ	MP + Imatinib	Alive after 8 months	t(9;14;22)(q34;q24;q11)
Francesc C et al., 1995	74 F	ET	INF α 2b P32	61 months	IgA λ	MP	Died after 3 months	NS
Philip M et al., 1995	94 F	ET	Alkylating + thiotepa	11 years	IgA κ	MP	NA	NS
Montserrat R et al., 1990	38 F	CNL	Without any therapy	7 years	κ	MP	Alive after 5 months	46XX; Ph(-)
Michalis M et al., 2009	63 F	CML	Imatinib	65 months	IgA κ	TD + Imatinib VAD Velcode	Alive after two years	NS
Pérez LM et al., 2007	63 M	Prostate adenocarcinoma	NA	NA	NA	NA	NA	NS
Rogulj IM et al., 2011	NA	CLL	NA	11 years		Without any therapy	NA	NS
Prósper F, et al, 1992	NA	ET	NA	5 years	NA	NA	NA	NS
Dorn GW et al., 1984	NA M	Hodgkin's disease	NA	NA	NA	NA	NA	NS
Tzilves D et al., 2007	74 M	gastrointestinal stromal tumor	Imatinib	1 month	IgA κ	MP + Imatinib	Died after 6 months	NS
Nowakowski et al., 2007	65 M	Penile myeloid sarcoma	NA	NA	NA	NA	Died after 16 months	NS
Monique A, 2010	71 M	Merkel cell carcinoma CLL	RFC	14 years	κ	CTX+P	Died after 6 months	NS
Hashimoto S et al., 1992	71 M	Diffuse large B cell malignant lymphoma	CHOP	32 months	IgA κ	Combination chemotherap	alive	NS
Derghazarian et al., 1974	65F	CML	busulphan	3 years	IgG κ	L	NA	46XX;22q-; Ph (+)
Zoumbos et al., 1987	57M	CNL	busulphan	5 years	κ	NA	NA	NS
Majhail NS et al., 2003	85 M	ET	hydroxyurea	50 months	IgG λ	Without any therapy	Refuse any treatment	NS
Majhail NS et al., 2003	54M	ET	Hydroxyurea	29 months	IgG κ	MP DOP	Died after 5 years	NS
Derghazarian C et al., 1974	65 F	ET	busulfan	7 years	IgG κ	Radiotherapy L + busulfan	Alive after 2 years	NS
Kough RH et al., 1978	75F	CLL	Chlorambucil	80 months	IgA κ	MP CTX	Died after 3 year	NS
Kough RH et al., 1978	58 M	CLL	Chlorambucil	4 years	κ	MP	Died after 1 year	NS

Table 1. Clinical data from cases of MM following other malignancies

CTX, cyclophosphamide; L, Phenylalanine mustard; MP, melphalan + prednisone; TD, Thalidomide + dexamethasone; VAD vincristine + liposomal doxorubicin + dexamethasone; MOP, MP + Vincristine; DOP, vincristine + doxorubicin + dexamethasone; RFC, fludarabine + cyclophosphamide + rituximab; CHOP doxorubicin + cyclophosphamide + vincristine + prednisolone; F, female; M, male; NA, not available; NS, not stated; SPE, serum protein electrophoresis; IE, immunoelectrophoresis; + combined with; - negative; \uparrow increased; CNL, chronic neutrophilic leukaemia; CLL, chronic lymphocytic leukemia; CML, Chronic myeloid leukemia; ET, essential thrombocythemia; L, Phenylalanine mustard; INF, interferon

(every cycle per month) and consistently showed good partial response. After the second and third cycles of consolidation chemotherapy, the percentages of plasma cells were separately 3% and 1%. Concentrations of IgA were 173 and 82 mg/dl, those of κ light chains were 567 and 255 mg/dl, and κ/λ ratios were 4.2:1 and 1.7:1. Bence-Jones proteinuria test results were consistently oppositive. B-scan ultrasound did not show any lesion in the bladder during follow up. The patient was advised to discontinue bortezomib treatment because of grade 3 toxicity (bortezomib-induced peripheral neuropathy) and refused to receive other therapy. Numbness of extremities gradually disappeared.

In June 2013, the patient presented with severe anemia (Hb, 52 g/L) and gross hematuria. B-scan ultrasound and cystoscopic examination confirmed the relapse of bladder cancer. A pathological examination revealed high-grade invasive urothelial carcinoma with invasion of the epithelial lamina propria. Bone marrow aspiration revealed 50% plasma cells. The patient received two cycles of the "VDZ" regimen, and the aforementioned symptoms were relieved. Very good partial remission was again achieved. However, the patient refused to receive further treatment and was discharged against doctor's advice.

Discussion

MM following other malignancies is a rare clinical entity. To our knowledge, only 23 cases of this condition have been reported in the literature: four cases involved MM following solitary tumors, such as those in lung cancer, colon adenocarcinoma, prostate adenocarcinoma, gastrointestinal stromal tumor, and penile myeloid sarcoma; four involved lymphoma; and 15 were incidences of MPNs, such as essential thrombocythemia, chronic lymphocytic leukemia, chronic myeloid leukemia, and chronic neutrophilic leukemia [1–24].

The etiopathogenetic factors of MM following other malignancies remain undetermined. Whether the development of MM is spontaneous or is accelerated by the treatment of other malignancies is difficult to prove. The occurrence of this type of MM can be explained by a number of factors [25]. Our patient, who has no history of alcohol or tobacco use, developed MM after 18 months of treatment with Pharmorubicin RD. In addition, the patient has no family history of cancer. Both *ras* and *p53* gene mutations were detected in the bone marrow mononuclear cells by PCR at the time of MM diagnosis; no chromosomal abnormality was found. The MM in our patient may have resulted from treatment with anti-carcinoma drugs. Anthracyclines inhibit DNA synthesis, block DNA replication, and create free oxygen radicals that damage the DNA. Anthracyclines can cause chromosomal abnormality, with toxicity accumulation being dose dependent. Other secondary malignancies were estimated at less than 2% within 10 years after anthracycline treatment. No case of MM induction by anthracyclines has been reported. This case is the first reported incidence of MM development after exposure to Pharmorubicin RD alone. However, our patient received localized intravesical Pharmorubicin RD instillation with no systemic chemotherapy for four cycles (total accumulated dose of 200

mg) without receiving any prior treatment for bladder cancer. Furthermore, no chromosomal abnormality was found in our patient. Therefore, evidence to prove that anti-bladder cancer therapy could possibly cause myeloma development was insufficient in this case.

The development of MM and bladder cancer involves genomic instability. Therefore, the patient may have possessed a genetic defect predisposing the development of frequent neoplasia. Both *ras* and *p53* genes are carcinogenic genes that are closely related to MM and bladder cancer. Mutations of these genes were also detected in our patient. These two genetic mutations may have triggered the occurrence of the two distinct malignancies. Another possible explanation for the biological mechanism of MM is that one genetic mutation (*ras* or *p53*) occurred at the onset of bladder cancer in the first stage, consequently creating a possible preneoplastic state for MM. The other gene (*p53* or *ras*) mutated in the second stage under immune-deficient conditions and resulted in overt MM. This condition is called a "two-hit phenomenon." However, the genetic mutations in bone marrow were undetected during biopsy and diagnosis of bladder cancer. However, the most likely explanation for the development of MM is predisposition to genetic defects.

The treatment process for this patient is also notable. The different progressive biological activities of both neoplasms, including the markedly divergent responses to therapies, contributed to a significant clinical dilemma. The presence of two neoplasms in one patient is a therapeutic challenge. A review of the literature showed that no standard treatment has been established for MM following other malignancies. Most cases in the literature temporarily received divergent treatment regimens for different cancers. This condition may have been caused by the superposition of side effects, particularly severe bone marrow failure, sepsis, and major organ failure caused by various antineoplastic agents, which may eventually result in death. MM following other malignancies has a relatively poor prognosis. Median disease-free survival was less than 10 months, even if the patients received regular chemotherapy without bortezomib.

In this report, our patient received bortezomib treatment. Bortezomib reversibly inhibits the 26S proteasome, which disrupts various cell signaling pathways and leads to cell cycle arrest, apoptosis, and inhibition of angiogenesis. Bortezomib has been approved and widely used as the first therapeutic proteasome inhibitor for patients with relapsed or refractory MM and mantle cell lymphoma [26]. Successful treatment of simultaneous MM and bladder cancer by bortezomib has not yet been reported. Nevertheless, in vitro and in vivo data from cell cultures and clinical trials support the hypothesis that bortezomib induces bladder cancer cell death and inhibits angiogenesis [27–30]. Bladder cancer rapidly relapsed and progressed because of the absence of a sensitive therapy, including TURBT and Pharmorubicin RD, at the early stage. Therefore, bortezomib was administered to our patient with MM and bladder cancer. Good clinical response was achieved for 20 months. Relapse of MM and bladder cancer occurred after discontinuation of bortezomib therapy. Complete remission was again achieved after three cycles of

bortezomib. Although direct evidence of the efficacy of bortezomib as a targeted therapy for bladder cancer is currently lacking, administration of bortezomib may be feasible because this drug is cytochrome independent. Further studies are required to improve the management of this rare case of coexisting multiple neoplasia.

To the best of our knowledge, this study is the first to report on an MM case following bladder cancer treated with Pharmorubicin RD alone. Genetic mutations may have been involved in the development of MM. The successful treatment of the condition with bortezomib may be used as a clinical basis for future treatment of concomitant MM and other malignancies.

Authors' Contribution

YH. Wang and FP. Peng have contributed equally to this work.

Acknowledgments

This study was partly supported by Tianjin Bureau of Public Health (No. 2010KZ105), Tianjin Medical University (No. 2010ky20), and Natural Science Foundation of Tianjin Municipal Science and Technology commission (No. 12ZCDZSY18000).

Disclosure

The authors do not have any conflict of interest.

References

- Rovira M, Cervantes F, Nomdedeu B, Rozman C (1990) Chronic neutrophilic leukaemia preceding for seven years the development of multiple myeloma. *Acta Haematol* 83: 94-95.
- Próspér F, Borbolla JR, Rifón J, Cuesta B, Fernández J, et al. (1992) Coexistence of essential thrombocythemia and multiple myeloma. *Ann Hematol* 65: 103-105.
- Arlen PM, Goldkland GA (1995) Multiple myeloma after treatment of essential thrombocythemia. *South Med J* 88: 79-81.
- Boneva R, Gercheva L, Todorov V, Dimitrova B (1996) Development of multiple myeloma in 2 patients with chronic pyelonephritis and long-term hemodialysis treatment. *Nephron* 73: 124.
- Wickenhauser C, Borchmann P, Diehl V, Scharffetter-Kochanek K (1999) Development of IgG lambda multiple myeloma in a patient with cutaneous CD30+ anaplastic T-cell lymphoma. *Leuk Lymphoma* 35: 201-206.
- Dorn GW, Baldwin JG Jr. (1984) Rapid development of myeloma in a patient with Hodgkin's disease. *J S C Med Assoc* 80: 599-600.
- Yeh GK, Axelrod MR (1979) Tumores rari et inusitati. Development of multiple myeloma in long term survivors of breast cancer. *Clin Oncol* 5: 175-177.
- Drasin H, Blume MR, Rosenbaum EH, Klein HZ (1979) Pulmonary hyalinizing granulomas in a patient with malignant lymphoma, with development nine years later of multiple myeloma and systemic amyloidosis. *Cancer* 44: 215-220.
- Grudeva-Popova J, Nenova I, Spasova M, Yaneva M, Beleva E, et al. (2013) Multiple myeloma in association with second malignancy. *JBUON* 18: 448-452.
- Keklik M, Sivgin S, Deniz K, Karaca H, Kontas O, et al. (2013) Coincidence of three solid tumors in a patient with multiple Myeloma. *Chin MedJ* 126: 1186-1187.
- Garipidou V, Vakalopoulou S, Tziomalos K (2005) Development of Multiple Myeloma in a Patient with Chronic Myeloid Leukemia After Treatment with Imatinib Mesylate. *The Oncologist* 10: 457-458.C
- Michael M, Antoniadis M, Lemesiou E, Papaminas N, Melanthiou F (2009) Development of Multiple Myeloma in a Patient with Chronic Myeloid Leukemia While on Treatment with Imatinib Mesylate for 65 Months. *The Oncologist* 14: 1198-1200.
- O.Selroos and A. van Assendelft (1977) Thrombocythaemia and Multiple Myeloma A Report on Two Cases. *Acts Med Scand* 201: 243-247.
- Lewis MJ, Oelbaum MH, Coleman M, Allen S (1986) An association between chronic neutrophilic leukaemia and multiple myeloma with a study of cobalamin-binding proteins. *British journal of haematology* 63: 173-180.
- RH Kough, AZ Makary (1978) Chronic lymphocytic leukemia (CLL) terminating in multiple myeloma: report of two cases. *Blood* 52: 532-6.
- Tanaka M, Kimura R, Matsutani A, Zaitsu K, Oka Y, et al. (1998) Coexistence of Chronic Myelogenous Leukemia and Multiple Myeloma Case Report and Review of the Literature. *Acta Haematol* 99: 221-223.
- Zoumbos NC, Chrysanthopoulos C, Starakis J, Kapatais-Zoumbos K (1987) Kappa light chain myeloma developing in a patient with chronic neutrophilic leukaemia. *British journal of haematology* 65: 504-505.
- Lewis MJ, Oelbaum MH, Coleman M, Allen S (1986) An association between chronic neutrophilic leukaemia and multiple myeloma with a study of cobalamin-binding proteins. *British journal of haematology* 63: 173-180.
- Shuster M, Causing W C (1971) Chronic lymphatic leukemia and lymphosarcoma terminating in multiple myeloma. *The Journal of the Medical Society of New Jersey* 68: 365-368.
- Hashimoto S, Kawano E, Hirasawa A, Morio S, Aotuka N, et al. (1992) Multiple myeloma in a patient in remission from malignant lymphoma. [Rinsho ketsueki] *The Japanese journal of clinical hematology* 33: 671-676.
- Tanaka M, Kimura R, Matsutani A, Zaitsu K, Oka Y, et al. (1998) Coexistence of chronic myelogenous leukemia and multiple myeloma. Case report and review of the literature. *Acta haematologica* 99: 221-223.
- Raz I, Polliack A (1984) Coexistence of myelomonocytic leukemia and monoclonal gammopathy or myeloma. Simultaneous presentation in three patients. *Cancer* 153: 83-85.
- Próspér F, Borbolla JR, Rifón J, Cuesta B, Fernández J, et al. (1992) Coexistence of essential thrombocythemia and multiple myeloma. *Annals of hematology* 65: 103-105.
- Kough RH, Makary AZ (1978) Chronic lymphocytic leukemia (CLL) terminating in multiple myeloma: report of two cases. *Blood* 52: 532-536.
- Aksoy M, Erdem S, Dinçol G, Kutlar A, Bakioglu I, et al. (1984) Clinical observations showing the role of some factors in the etiology of multiple myeloma. A study in 7 patients. *Acta haematologica* 71: 116-120.
- Field-Smith A, Morgan GJ, Davies FE (2005) Bortezomib (Velcade™) in the Treatment of Multiple Myeloma. *Oncol* 3: 19-22.
- Qi W, White MC, Choi W, Guo C, Dinney C, et al. (2013) Inhibition of inducible heat shock protein-70 (hsp72) enhances bortezomib-induced cell death in human bladder cancer cells. *PLoS One* 8: e69509.
- Papageorgiou A, Kamat A, Benedict WF, Dinney C, McConkey DJ (2006) Combination therapy with IFN-alpha plus bortezomib induces apoptosis and inhibits angiogenesis in human bladder cancer cells. *Mol Cancer Ther* 5: 3032-3041.
- Lashinger LM, Zhu K, Williams SA, Shrader M, Dinney CP, et al. (2005) Bortezomib abolishes tumor necrosis factor-related apoptosis-inducing ligand resistance via a p21-dependent mechanism in human bladder and prostate cancer cells. *Cancer Res* 65: 4902-4908.
- Kamat AM, Karashima T, Davis DW, Lashinger L, Bar-Eli M, et al. (2004) The proteasome inhibitor bortezomib synergizes with gemcitabine to block the growth of human 253JB-V bladder tumors in vivo. *Mol Cancer Ther* 3: 279-290.

Submit your manuscript to a JScholar journal and benefit from:

- ✦ Convenient online submission
- ✦ Rigorous peer review
- ✦ Immediate publication on acceptance
- ✦ Open access: articles freely available online
- ✦ High visibility within the field
- ✦ Better discount for your subsequent articles

Submit your manuscript at
<http://www.jscholaronline.org/submit-manuscript.php>