

## Primary Extramedullary Myeloid Tumor of Testis: A Rare Entity

Kuanr DR<sup>1</sup>, Kanwal NK<sup>2</sup>, Bora GS<sup>3</sup>, Mavuduru RS<sup>4,\*</sup>, Kakkar N<sup>5</sup>, Mandal AK<sup>6</sup>

<sup>1</sup>Senior Resident, Department of urology, Postgraduate Institute of Medical Education & Research, Chandigarh, India

<sup>2</sup>Senior Resident, Department of urology, Postgraduate Institute of Medical Education & Research, Chandigarh, India

<sup>3</sup>Assistant professor, Department of urology, Postgraduate Institute of Medical Education & Research, Chandigarh, India

<sup>4</sup>Associate professor, Department of urology, Postgraduate Institute of Medical Education & Research, Chandigarh, India

<sup>5</sup>Professor, Department of Pathology, Postgraduate Institute of Medical Education & Research, Chandigarh, India

<sup>6</sup>Professor & head, Department of urology, Postgraduate Institute of Medical Education & Research, Chandigarh, India

\*Corresponding author: Ravimohan S Mavuduru; Associate Professor; Department of Urology; Nehru hospital PGIMER Chandigarh; Tel: 919417532955; Email: Ravismi2003@yahoo.com

Received Date: October 12, 2017 Accepted Date: November 26, 2017 Published Date: November 28, 2017

Citation: Kuanr DR (2017) Primary Extramedullary Myeloid Tumor of Testis: A Rare Entity. Case Reports: Open Access 1: 1-3.

### Abstract

Extramedullary myeloid tumors are rare solid tumors comprising of immature cells of myeloid lineage. These tumors are commonly associated with acute myeloid leukemia. Primary extramedullary myeloid tumor of testis is a very rare entity. We report a patient of 24 year old who presented with right testicular mass and elevated lactate dehydrogenase levels. Histopathological analysis of radical orchiectomy specimen revealed a tumor with large areas of hyalinisation and tumor cells that were 3-4 times larger than mature lymphocytes. Immunohistochemistry (IHC) stain for myeloperoxidase (MPO), CD20 showed strong cytoplasmic positivity. Overall features were consistent with extramedullary myeloid tumor. The present case highlights the rarity of this testicular tumor and its management.

**Keywords:** Extra-medullary myeloid tumor, Acute myeloid leukemia, Myeloperoxidase

### Introduction

Extramedullary myeloid tumours also known as chloromas, myeloid sarcomas, chloroleukemias, myeloblastomas, myelocytomas, granulocytic sarcomas, are rare solid tumours comprising of immature cells of myeloid lineage. These tumours are commonly associated with acute myeloid leukemia (AML), however association with chronic myeloproliferative disorders like chronic myeloid leukemia, polycythemia vera, primary myelofibrosis has also been reported in literature [1]. Rarely they have been reported as initial manifestation of AML without involvement of the bone marrow [2]. The testicles are rare sites for extramedullary myeloid tumors and only few case reports appear in literature [3]. We report a case of primary testicular extramedullary myeloid tumor without pre-existing or concomitant diagnosis of leukemia.

©2017 The Authors. Published by the JScholar under the terms of the Creative Commons Attribution License <http://creativecommons.org/licenses/by/3.0/>, which permits unrestricted use, provided the original author and source are credited.

### Case report

A 24-year old man presented with gradually increasing painless right testicular mass for six months. Serum alpha fetoprotein and  $\beta$  HCG levels were in normal range, however serum lactate dehydrogenase level (494U/L) was elevated. Complete blood count showed normal total leukocyte count, without the presence of any morphologically abnormal cells in peripheral blood. Ultrasonography revealed a well-defined 4x3 cm mass in right testicle and contra lateral testicle was normal. Computed tomography of the abdomen showed a ill defined soft tissue mass at L3 level. The patient underwent right radical orchiectomy (Figure 1). Histopathological analysis revealed a tumor with large areas of hyalinisation with tumor cells that were three to four times larger than mature lymphocytes (Figure 2). Immunohistochemistry (IHC) stain for myeloperoxidase (MPO) and CD 20 showed strong cytoplasmic positivity (Figure 3).

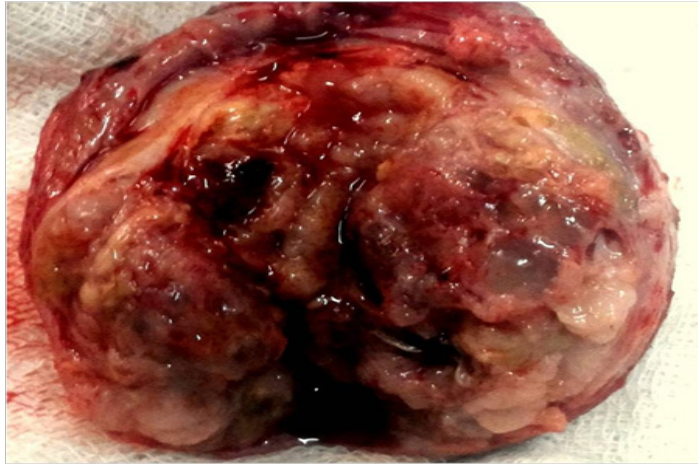


Figure 1: Cut open orchietomy specimen

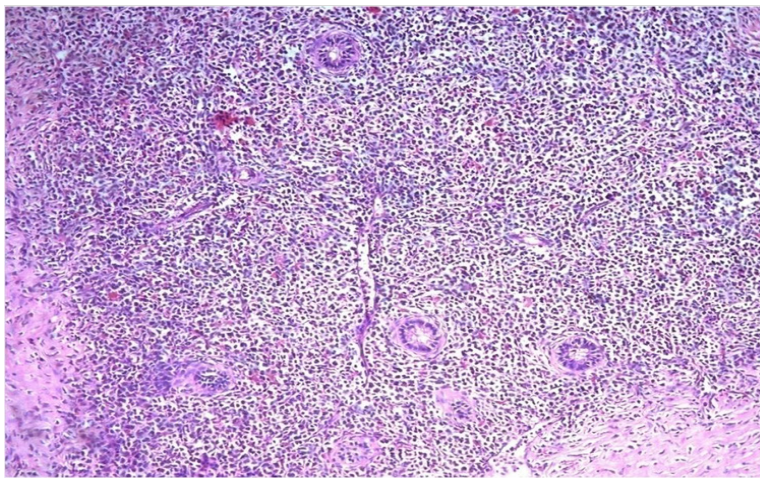


Figure 2: Non-sustained polymorphic ventricular tachycardia following modified Valsalva maneuver.

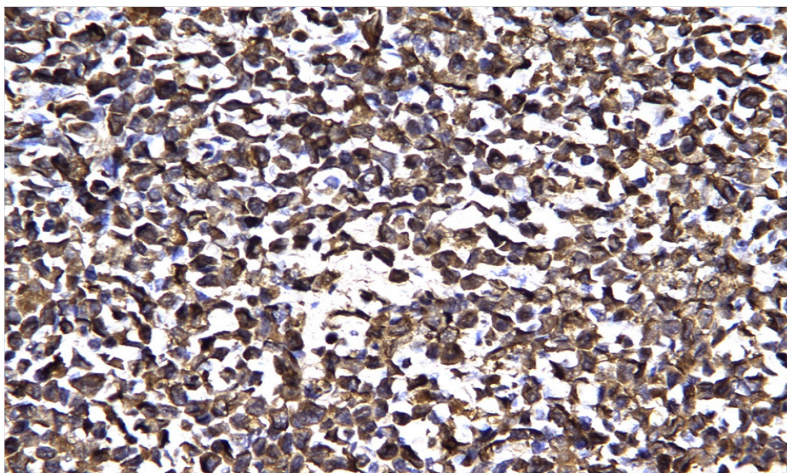


Figure 3: Immature myeloid cells positive for myeloperoxidase.

Staining for cytokeratin, desmin, myogenin were negative and overall features were consistent with extra-medullary myeloid tumor. Bone marrow biopsy revealed no evidence of infiltration by immature cells. Patient was started on induction chemotherapy with Cytarabine. The patient responded well and the disease was in remission till the last follow-up at 6 months.

## Discussion

The usual sites of involvement of extra-medullary myeloid tumors are skin, gums, bone, central nervous system, orbit, lymph nodes, and small intestine [4]. These tumors are commonly diagnosed in young adults and observed usually with concurrent bone marrow disease. Incidence is relatively more with leukemias with prominent monocytic differentiation (acute myelomonocytic or acute monocytic leukemia, chronic myelomonocytic leukemia). Primary extra-medullary myeloid tumor of testis without pre-existing or concomitant diagnosis of leukemia is a very rare entity and is a poor prognostic factor [5]. Identification of the granulocytic characteristics in the tumor cells clinches the histological diagnosis. Differential diagnoses include large cell lymphoma, plasmacytoma, orchitis, and seminoma. IHC helps in identifying antigens (MPO, CD13, CD33, CD43, CD117, CD 20, lysozyme, and CD68) that are associated with myeloid lineage [6]. In the present case, the tumor was positive for MPO and CD 20. Acute leukemia usually manifests shortly after the appearance of primary extra-medullary myeloid tumors (range 1–18 months). Therefore, these tumors are considered initial manifestations of acute leukemia, rather than a localized process [7]. Various modalities of treatment are used in the management of extra-medullary myeloid tumors. The options are chemotherapy, radiotherapy and surgery. Chemotherapy is considered to be the best treatment strategy. Surgery is useful in cases with symptomatic compression due to the tumor. Radiotherapy is considered for consolidation of chemotherapy and treating lesions persisting after chemotherapy [8].

## Conclusion

Primary extra-medullary myeloid tumors are rare tumors of testis and should be taken into consideration in the differential diagnoses of undifferentiated neoplasia. Immunohistochemical techniques are helpful in making a rapid diagnosis and chemotherapy is the treatment of choice in these cases.

## References

- 1) Brunning RD, Matutes E, Flandrin G, et al. Acute myeloid leukemia not otherwise categorized: myeloid sarcoma. In: Jaffe ES, Harris NL, Stein H, et al, eds. (2001) World Health Organization Classification of Tumours: Pathology and Genetics of Tumours of Haematopoietic and Lymphoid Tissues. Lyon, France: IARC Press: 104-105.
- 2) Wong WS, Loong F, Ooi GC, Tse TC, Chim CS (2004) Primary granulocytic sarcoma of the mediastinum. *Leuk Lymphoma*.45:1931-1933.
- 3) Eggener SE, Abrahams A, Keeler TC (2004) Granulocytic sarcoma of the testis. *Urology* 63:584-585.
- 4) Cheah KL, Lim LC, Teong HH, Chua SH (2002) A case of generalized cutaneous granulocytic sarcoma in an elderly patient with myelodysplastic syndrome. *Singapore Med J* 43:527-529.
- 5) Valbuena JR, Admirand JH, Lin P, Medeiros LJ (2005) Myeloid sarcoma involving the testis. *Am J Clin Pathol* 124: 445-452.
- 6) Campidelli C, Agostinelli C, Stitson R, Pileri SA (2009) Myeloid sarcoma: extramedullary manifestation of myeloid disorders. *Am J Clin Pathol* 132:426-437.
- 7) Heaney JA, Klauber GT, Conley GR (1983) Acute leukemia: diagnosis and management of testicular involvement. *Urology* 21:573-577.
- 8) Bakst RL, Tallman MS, Douer D, Yahalom J (2011) How I treat extramedullary acute myeloid leukemia. *Blood*. 118:3785-393.

Submit your manuscript to a JScholar journal and benefit from:

- ¶ Convenient online submission
- ¶ Rigorous peer review
- ¶ Immediate publication on acceptance
- ¶ Open access: articles freely available online
- ¶ High visibility within the field
- ¶ Better discount for your subsequent articles

Submit your manuscript at  
<http://www.jscholaronline.org/submit-manuscript.php>