

A 28 year-old male had Levetriacetam induced drug eruptions- Skin desquamation and hyperpigmentation

Prajith V*

Sri Ramakrishna Institute of Paramedical Sciences, College of pharmacy Siddhapudur, Coimbatore, India

*Corresponding author: Prajith V, Sri Ramakrishna Institute of Paramedical Sciences, College of pharmacy Siddhapudur, Coimbatore, India, Tel: 7010072560, E-mail: prajithkanna@gmail.com

Received Date: December 20, 2020 Accepted Date: January 20, 2021 Published Date: January 22, 2021

Citation: Prajith V (2021) A 28 year-old male had Levetriacetam induced drug eruptions- Skin desquamation and hyperpigmentation. Case Reports: Open Access 6: 1-4.

Abstract

Apart from levetriacetam inducing hyperpigmentation, on regular exposure of levetriacetam, patient has developed late-stage desquamation of the skin with maculopapular rashes. 28yr old patient was admitted in the I.C.U with the history of Road Traffic Accident (RTA) and diagnosed with Subarachnoid haemorrhage (SAH). He was administrated with levetriacetam with other drugs.

On continuous exposure up to 8 days of IV levetriacetam 500mg twice daily, there was development of skin eruptions spreading all over the body. With this evidence, it shows that levetriacetam is a possible cause of skin desquamations and hyperpigmentation.

Keywords: Levetriacetam; Hyperpigmentation; Desquamation; Adverse Drug Reaction

Introduction

Levetriacetam is an antiepileptic agent used for partial and generalized seizure [1]. The mechanism of action is modulation of synaptic neurotransmitter release through binding to the synaptic vesicle protein SV2A in the brain. Levetriacetam is the drug of choice for traumatic brain injury patients when compared to phenytoin as it has low rate of hospital stay according to Brain Trauma Foundation and the American Academy of Neurology (AAN) for the management of severe TBI but the prophylactic use of Levetriacetam is not appropriately prescribed [2, 4]. Antiepileptic drugs have a class effect of cutaneous skin reactions. To our knowledge, this is the first report of serious skin desquamations that was observed after IV administration of Levetriacetam.

Patient information

A 28year old male patient was admitted in emergency room with complaints of breathlessness and cough. He had a history of RTA (19 days back) and was diagnosed to have SAH / Fracture at right occipital bone/ right temporal bone/ multiple rib fractures- right-side 1st-9th Rib/ D8 compression fracture with spinal cord contusion/ paraplegia.

Past history

The patient had a road traffic accident and he undergone D7, D8, D9 pedicle screw fixation with rod and D8 laminectomy (9 day after RTA) and he was discharged.

Subjective

The patient had complaints of breathlessness with cough since 3 days.

Investigations

The patient is Non-diabetic/Normotensive with normal cardiovascular function, decreased airway entry on the right side with crepts (hemi thorax) (O₂ saturation -96%), physical examination revealed that GCS score was 11. CT chest shows right moderate pleural effusion, upper lobe consolidation and collapse, multiple spine fracture, right scapula fracture and fractures at D1, D2, D3, D4 vertebrae.

CT chest showed CORAD-1 with right pleural effusion.

Laboratory investigations include BUN (blood urea Nitrogen) - 12mg/dl; SCr- 0.49 mg/dl; sodium- 134mEq/L; potassium- 3.6mEq/L. The levels of potassium was not maintained, it was

reducing. Potassium levels were monitored and oral potassium chloride syrup was added to the regimen (K levels- 3.6mEq/L; 3.3 mEq/L; 3.8 mEq/L; 3.5 mEq/L; 3.4 mEq/L; 3.2 mEq/L; 2.3 mEq/L).

Microbiological examination: Swab sample was obtained from ET tube and the organism identified was *Pseudomonas aeruginosa* which caused the spike in the temperature.

Diagnosis and treatment

Medications given were Inj. Pantoprazole 40mg BD, Inj. Thiamine 200mg on 100ml NS, Inj. Ondansetron 4mg IV BD Inj. Levetriacetam 500mg IV BD, Inj., Piperacillin/Tazobactam 4.5mg IV 8th hourly and Inj. Clarithromycin 500mg BD. All these medication where given for 8 days. Piperacillin skin test was done and it is negative. Apart from these, KCl syrup 45ml/day was given for 3 days and linezolid 600 mg BD with meropenam 1.5mg IV infusion over 3 hours/day was given for 2 days after stopping piperacillin antibiotic.

The patient was given with nasal O₂ 6 litres/ml for first day, since the O₂ saturation was not stabilizing, he was intubated(tracheostomy) with BIPAP ventilator, using Inj.fentanyl (50mcg), Inj. Propofol 50mg, inj. Atracurium 25mg. The patient was placed in mechanical ventilator with tidal volume 450ml, PEEP- 8% and FiO₂- 80%. After this process, the patient was sedated with Alprazolam 2mg OD with Reyle's tube feeding. ABG was taken, pH- 7.3, PO₂- 91.1; PCO₂- 38.2. Sedation is continued with fentanyl- 50mcg and midazolam- 25mg continuous IV infusion. Temperature was high up to 103.6 °F on day 4 from the day of admission. Paracetamol 650mg PO tid was given for 8 days Bed sore was observed and skin desquamation was seen in the gluteus maximus region with hyperpigmentation on the maxillary region on day 5 and maculopapular rash was observed on the chest region on day 3.

Tachycardia was noted in the Ambulatory ECG Monitoring, ECHO was taken, and it showed mild- moderate cardiac contractibility. Inj noradrenaline was added to the region as an inotropic agent. It was stopped after 3 days of administration as IV infusion. The next day of identification of skin eruptions, the desquamation spread to other parts of gluteus maximus and gluteus medius. Consultation with a dermatologist was done and the skin eruptions were confirmed as drug induced reaction. This Desquamation and hyperpigmentation might be caused by Levetriacetam [1]. Causal Assessment was made with Naranjo scale which categorizes the adverse effect as possible event. Levetriacetam was stopped (totally 8 grams in 8 days) after causal assessment and treatment advice was given by the dermatologist.

Treatment for Skin reaction

The patient was prescribed with Fexofenadine 120mg PO; Levocetirizine 5mg PO and cotrimoxazole dusting powder for local application tid. The skin eruptions were settled but the patient was not available for further investigations and rechallenge of Levetriacetam.

Discharge and follow up

The patient was shifted to government hospital as requested by the patient's caretaker for further treatment so the follow up was not completed after dechallenging the drug

Discussion

Levetriacetam is commonly used antiepileptic drug which also makes it for inappropriate use. Levetriacetam has to be prescribed when GCS score is ≥ 8 but in this case the patient was having an initial GCS score of 11 [2, 3]. Fixed drug eruptions (FDE) is cutaneous drug induced reactions which occurs as a hyperpigmentation initially and will develop lesions later [5]. The desquamation of skin was suspected due to levetriacetam as there was hyperpigmentation on day 3 as shown in the picture 1 and maculopapular rash as shown in the picture 2 which is compared to that of case reported by Algahtani et al which is a strong evidence that levetriacetam is the causative agent.

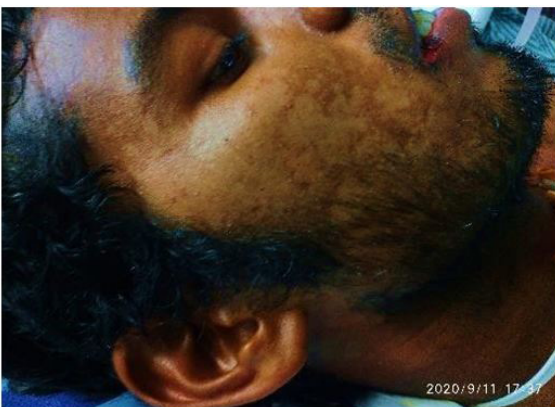

Figure 1: hyperpigmentation on the face

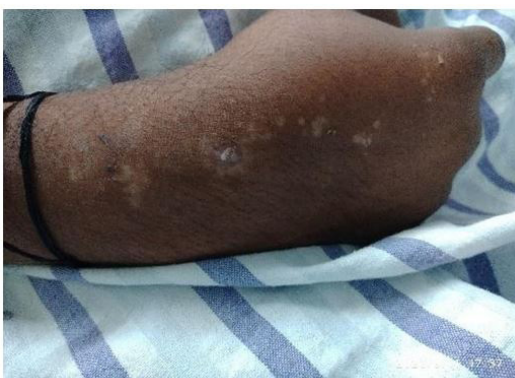

Figure 2: 'lighten up' hyperpigmentation on wrist

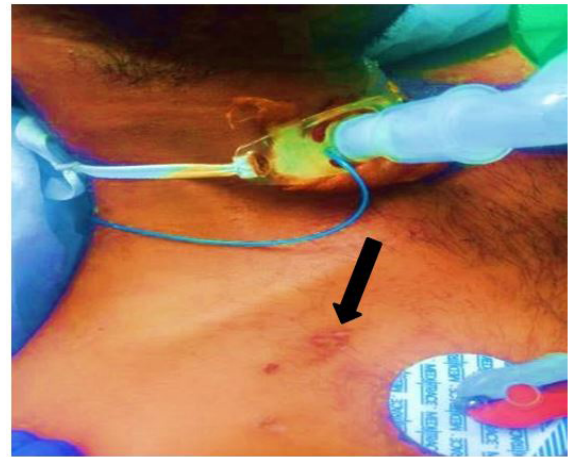


Figure 3: Maculopapular rash on chest region

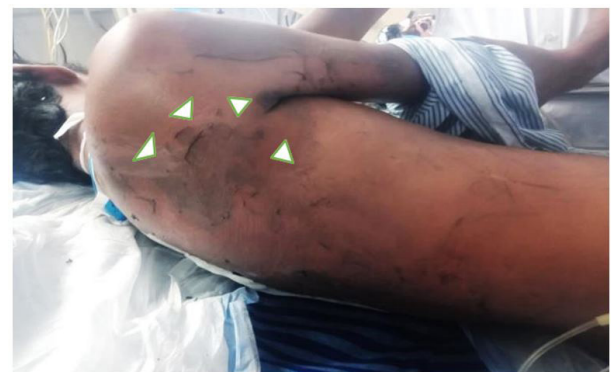

Figure 4: Desquamation of skin in acromial, dorsal region, lumbar region

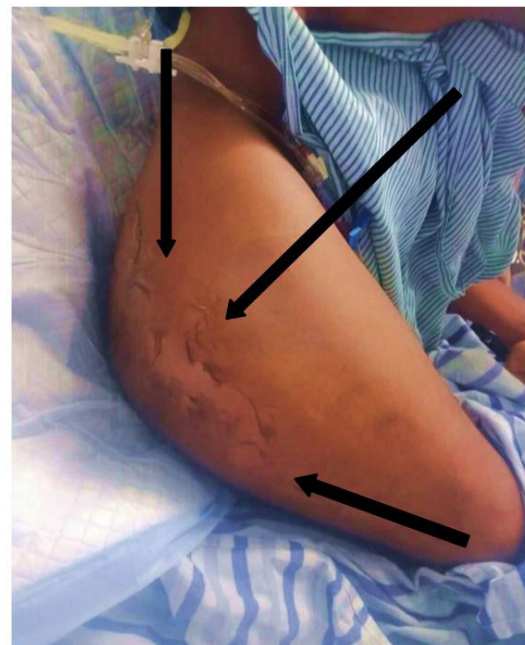

Figure 5: Severe Skin Desquamation on gluteal region

References

1. Algahtani H, Marghalani S, Satti M, Shirah B (2017) Levetiracetam-Induced Skin Hyperpigmentation: An Extremely Rare Undesirable Side Effect. *J Epilepsy Res* 7: 106-8.
2. Harris L, Hateley S, Tsang KT (2020) Impact of anti-epileptic drug choice on discharge in acute traumatic brain injury patients. *J Neurol* 267: 1774–9.
3. Inaba K, Menaker J, Branco BC (2013) A prospective multicenter comparison of levetiracetam versus phenytoin for early posttraumatic seizure prophylaxis. *J Trauma Acute Care Surg* 74: 766-73.
4. Torbic H, Forni AA, Anger KE, Degrado JR, Greenwood BC. Use of antiepileptics for seizure prophylaxis after traumatic brain injury. *Am J Health Syst Pharm* 70: 759-66.
5. Fixed Drug Eruptions.

Submit your manuscript to a JScholar journal and benefit from:

- ¶ Convenient online submission
- ¶ Rigorous peer review
- ¶ Immediate publication on acceptance
- ¶ Open access: articles freely available online
- ¶ High visibility within the field
- ¶ Better discount for your subsequent articles

Submit your manuscript at
<http://www.jscholaronline.org/submit-manuscript.php>