

## Cardiac Magnetic Resonance Imaging Study with Adenosine-Stress-Perfusion in a Patient with MRI-Compatible Pacemaker

Oliver Strohm<sup>1</sup>, Tilman Markert<sup>2</sup>, Christian Plathow<sup>3</sup>

<sup>1</sup>Adjunct Research Associate Professor, University of Calgary, Germany and Libin Cardiovascular Institute of Alberta, Calgary, Canada

<sup>2</sup>Tilman Markert, Zentrum fuer Kardiologie, Baden-Baden and Zentrum fuer Herzdiagnostik Baden-Baden Eichelgartenstrasse 2, D-76530 Baden-Baden, Germany

<sup>3</sup>Christian Plathow, Radiologie Baden-Baden and Zentrum fuer Herzdiagnostik Baden-Baden, Rotenbachtalstrasse 5 D-76530 Baden-Baden, Germany

\***Corresponding author:** Oliver Strohm, Adjunct Research Associate Professor, University of Calgary, Germany and Libin Cardiovascular Institute of Alberta, Calgary, Canada, Tel: +49 7221 30229-0; Fax: +49 7221 30229-59; E-mail: info@drstrohm.de

Received Date: August 20, 2014 Accepted Date: October 10, 2014 Published Date: October 15, 2014

Citation: Oliver Strohm et al. (2014) Cardiac Magnetic Resonance Imaging study with adenosine-stress-perfusion in a patient with MRI-compatible pacemaker. J Cardio Vasc Med 2: 1-2

A 62 year old patient with left main stenting had undergone DDD-pacemaker implantation for syncope with third-degree AV-block (Medtronic SureScan). He presented with chest pain with exertion, a stress echocardiography was not considered diagnostic for ischemia due to paced rhythm and a cardiac Magnetic Resonance Imaging (CMR) study was ordered.

After activation of the „sure-scan“ prior to the, an adenosine CMR study was performed, using standard protocols for, tissue characterisation, perfusion imaging and late Gadolinium enhancement (LGE) using standard contrast media (Magnevist<sup>®</sup>, Schering, Germany). T1 and T2 imaging was performed covering thoracic and abdominal regions as per local protocol.

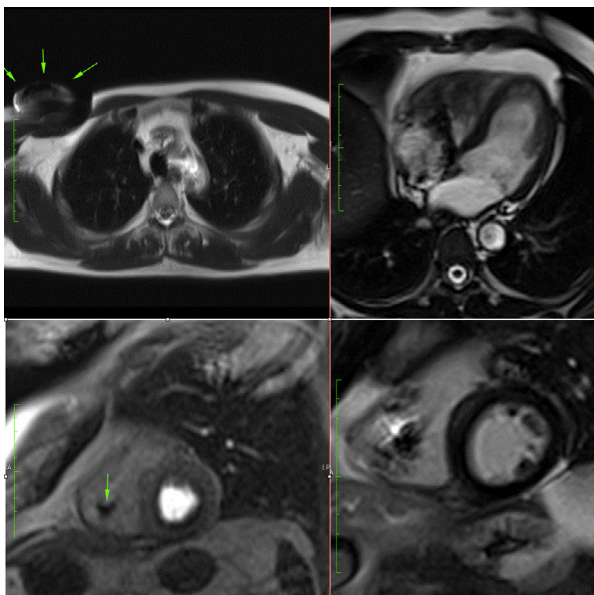
Left ventricular (LV) volumes and mass were normal (LVEDV 135 ml = 0.8 ml/m; stroke volume 90 ml; LV mass 113 g = 0.6 g/m), T2-images did not show myocardial edema. Perfusion imaging were compatible with mild hypertensive heart, LGE images did not show any relevant uptake and the study was interpreted negative for ischemia.

Interrogation of the pacemaker immediately after the study was performed by a Cardiologist and „sure-scan“ mode was terminated. No changes in sensing and pacing parameters were noted.

An additional coronary X-ray angiography two weeks later for sudden onset chest pain with negative troponin-study demonstrated open left main stent and no additional relevant stenoses.

To our knowledge, this is the first published study of a routine CMR study with a complete cardiac functional and perfusion protocol and thoracic and abdominal imaging in a patient with an MRI-compatible pacemaker, no relevant image distortion was noted. This case demonstrates the clinical feasibility of advanced cardiac imaging by CMR in the presence of an MRI-compatible pacemaker.

**Summary:** We report about a cardiac MRI examination including adenosin-stress testing in a patient with an MRI-suitable pacemaker. Image quality was not significantly altered and no complication occurred.



**Figure 1:**

Left upper:

Axial T2 weighted image showing the pacemaker (arrows) in the right subpectoral region

Right upper:

SSFP cine image in 4-chamber view orientation in diastole

Left lower

Perfusion image after 3 minutes of adenosine infusion with mild subendocardial perfusion defect in a non-ischemic distribution pattern, consistent with ring-artifact

Right lower

Late Gadolinium Enhancement image in short axis orientation, showing normal myocardial appearance without relevant uptake

**Submit your manuscript to JScholar journals  
and benefit from:**

- ¶ Convenient online submission
- ¶ Rigorous peer review
- ¶ Immediate publication on acceptance
- ¶ Open access: articles freely available online
- ¶ High visibility within the field
- ¶ Better discount for your subsequent articles

Submit your manuscript at  
<http://www.jscholaronline.org/submit-manuscript.php>